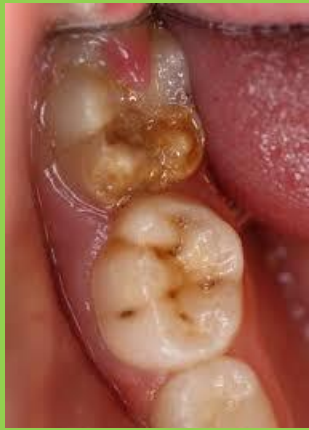
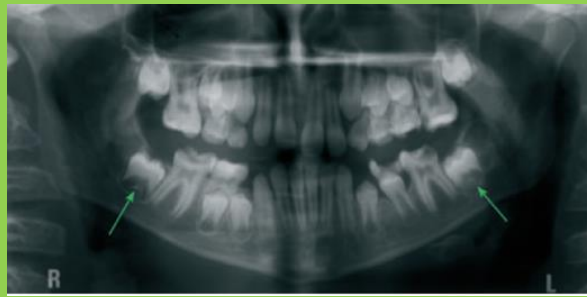
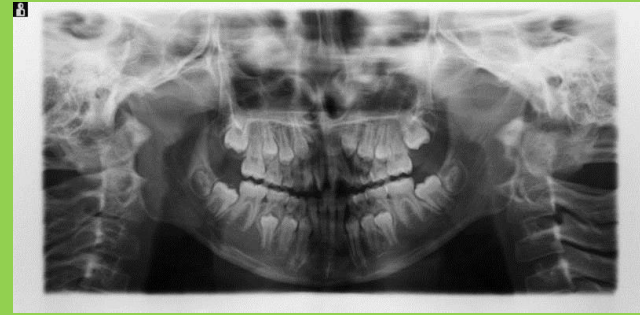

INSPECT, SYMPTOMS  
Sensitivity and or caries,  
more brown than yellow



CHECK OPG. Are 7's at  
Bifurcation. If not expect  
tipping.

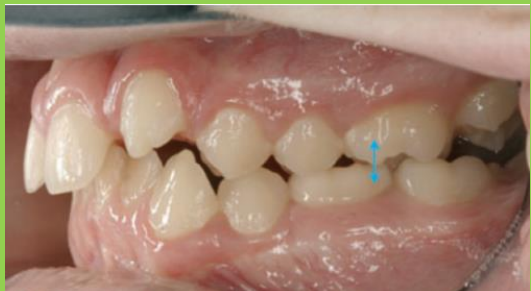

ARE 3<sup>rd</sup> molars present?  
Usually appear on OPG  
from 10-11 years



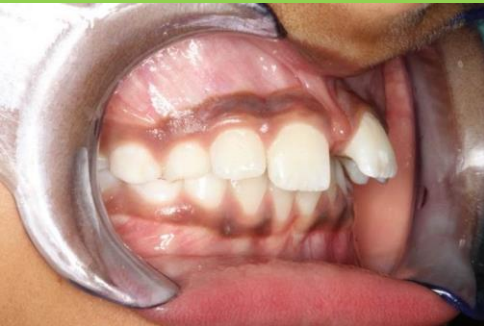**DECISION TO EXTRACT**

**Management of Hypomineralized  
permanent 1<sup>st</sup> molar- Decision Flow  
Pathway when deciding to extract**

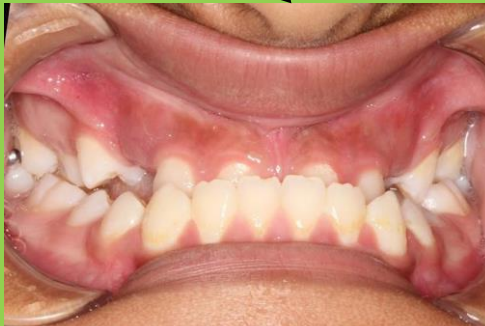


Is teeth crowded or space? More  
the crowding, overjet or underbite,  
greater need for space maintainer  
before or within 1-2 weeks after  
the extraction

CHECK OPPOSING OCCLUSION. If lower 6  
carious, consider extracting upper 6 OR 7?



Class 2 or 3- large overjet or  
Underbite. Seek an  
orthodontist opinion before  
any teeth extractions.

Dr Andrew Chang  
Orthodontist  
Suite 17-18/15 Kildare Rd  
Blacktown NSW 2148  
info@greatsydneysmiles.com.au  
Ph: 02-8814-9941